



# Prolonged Enhancement of a Demyelinating Lesion Mimicking Lymphoma

Paula Hardeman, PA-C, Elliot Frohman, MD, PhD, FAAN, Benjamin Greenberg, MD, MHS  
Department of Neurology and Neurotherapeutics, University of Texas Southwestern Medical Center, Dallas, TX



## Objective

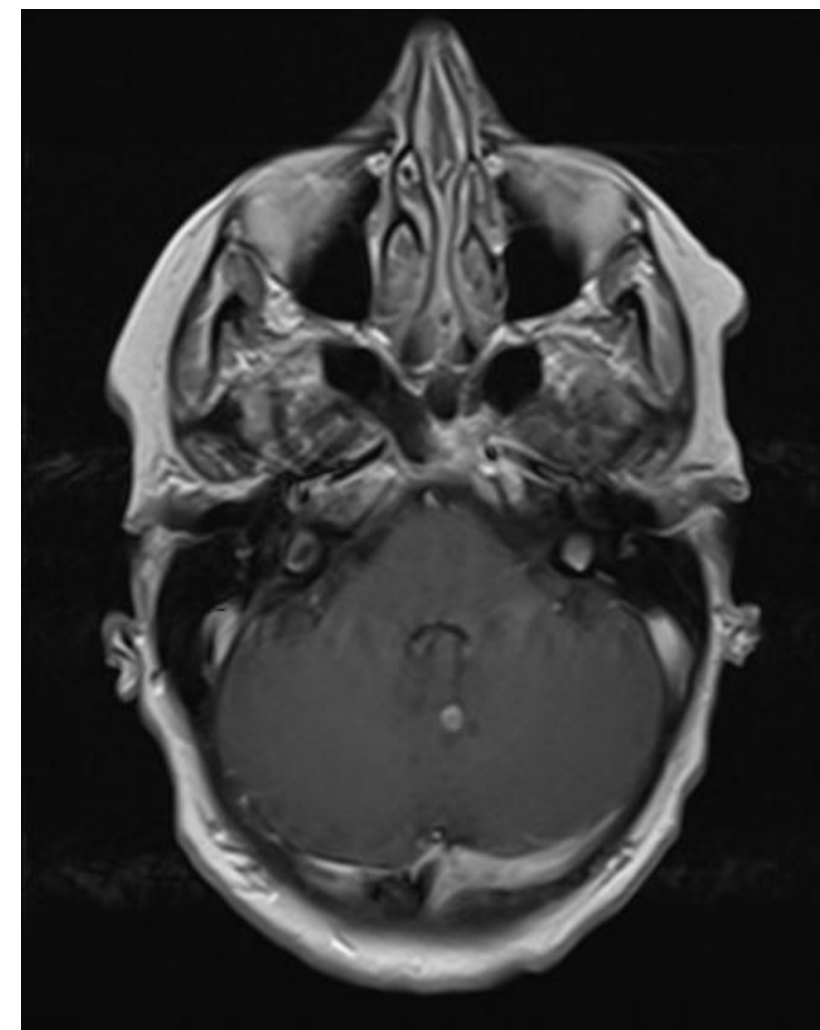
To describe a detailed case presentation of prolonged enhancement of a demyelinating lesion that mimics lymphoma.

## Introduction

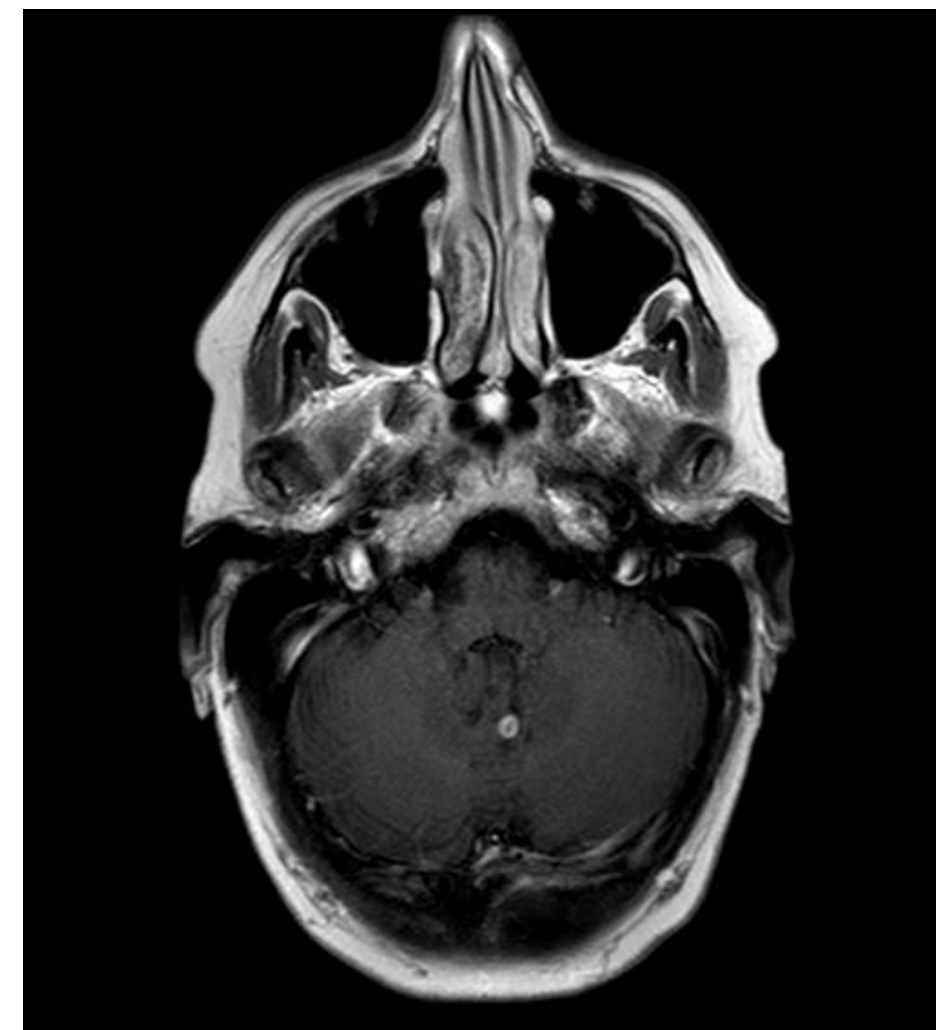Primary Central Nervous System Lymphoma (PCNSL) is characterized as a rare group of non-Hodgkins lymphoma, typically of B-cell origin, whose incidence has increase over the last three decades. Albeit the main risk for PCNSL has been immunodeficiency, recent studies have published reports that the incidence among immunocompetent patients has increased. Typically PCNSL has magnetic resonance imaging (MRI) findings similar to those in demyelinating diseases. PCNSL can present as unifocal or multifocal homogeneous enhancing lesions on MRI.

## Case Presentation

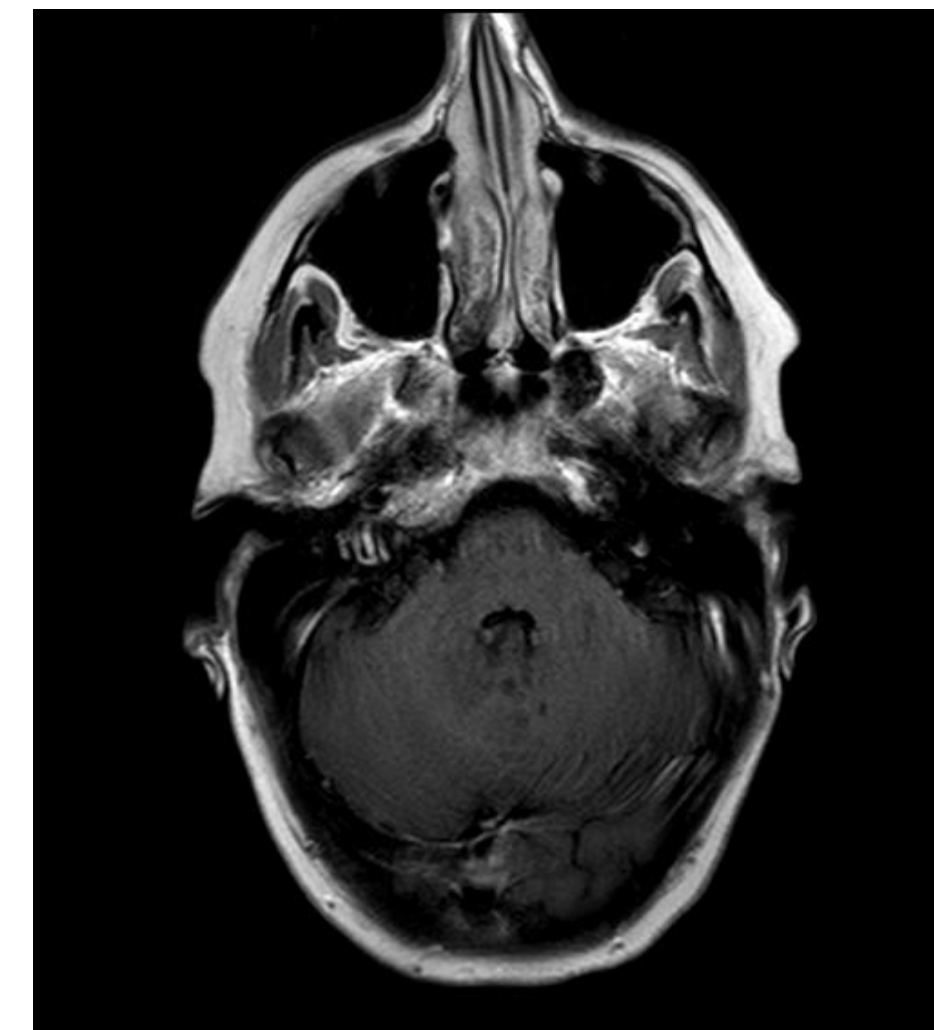
We present the case of 61 year-old Caucasian female with a one year history of relapsing remitting multiple sclerosis that was being treated with interferon beta 1a who on routine brain MRI had a new enhancing lesion that was suspicious for neoplasm. She did not have any new symptoms at the time of the initial MRI. The lesion's enhancement pattern persisted for over 6 months. She had repeat lumbar punctures for cerebrospinal fluid (CSF) analysis. She had flow cytometry of her CSF which revealed a slight proliferation of B-cells initially but subsequent CSF analysis was inconclusive. Repeated brain MRI and MR spectroscopy continued to reveal an enhancing lesion concerning for neoplasm. After six months her enhancement resolved.



Initial MRI



90 days



180 days

## Conclusions

Currently there is limited diagnostic criteria and/or testing to help discern changes on MRI that are suggestive of PCNSL in patients with demyelinating diseases. An immunocompromised status and immunodeficiency are the main risk factors for PCNSL, and frequently patients with demyelinating diseases are treated with chemotherapy drugs. PCNSL incidence is increasing in immunocompetent patients. This case history and imaging represents the need for better diagnostic testing in patients with demyelinating diseases who have changes that are concerning for PCNSL.

## Disclosures

- Paula Hardeman has received consulting fees from Pfizer and Accordia.
- Dr. Greenberg has received consulting fees from DioGenix, Sanofi Aventis, Biogen Idec and the Greater Good Foundation. He has equity in DioGenix. He has received grant support from Amplimmune, Accelerated Cure Project and Guthy-Jackson Foundation.
- Dr. Frohman has received speaker and consulting fees from Biogen, TEVA, Accordia, and Novartis and consulting fees from Genzyme and Abbott.